

# Is One Cage Enough in Posterior Lumbar Interbody Fusion: A Comparison of Unilateral Single Cage Interbody Fusion to Bilateral Cages

Guy R. Fogel, MD, John S. Toohey, MD, Arvo Neidre, MD, and John W. Brantigan, MD

**Abstract:** Posterior lumbar interbody fusion (PLIF), as recommended with bilateral lumbar interbody cages and pedicle screw fixation, has increased the successful fusion rate to nearly 100%. Presently, a unilateral approach to the disc space with a variant of PLIF, the trans-foraminal interbody fusion is often used. There are few clinical studies of unilateral interbody fusion. The clinical and fusion results of unilateral interbody fusion are important as the usage of trans-foraminal interbody fusion procedure increases. This retrospective study of 26 consecutive patients treated with a unilateral cage asks whether fusion healing and clinical outcome is comparable with that obtained with bilateral cages. In this study, there were no pseudarthroses, instrumentation failures, or significant subsidence at any of the single cage levels. Disc space height and foraminal height were restored by the surgery and maintained at last follow-up. Using Prolo scores, 23/26 patients had clinical success (88%), and 3 were unsuccessful. Fusion was successful at all single cage fusion levels and overall in 23/26 (88%) reviewing all levels of fusion. In conclusion, fusion and clinical success rates were not diminished by the use of a unilateral interbody cage rather than the recommended 2 cages. This retrospective comparative study is a Level III-2 Therapeutic Study investigating the results of unilateral PLIF with a single interbody cage compared with historical series with interbody cages.

**Key Words:** PLIF, TLIF, interbody fusion orthosis, cage, pedicle screw, degenerative disc disease, intervertebral disk displacement/pathology/radiography/\*surgery, middle aged, spinal fusion/\*instrumentation/\*methods, treatment outcome

(*J Spinal Disord Tech* 2007;20:60–65)

Received for publication January 31, 2006; accepted June 6, 2006.  
From the South Texas Orthopaedic and Spinal Surgery Associates, 9150 Huebner Road, San Antonio, TX 78240.

Device status: The Lumbar interbody carbon fiber Cage and the VSP Spinal Fixation System are approved by the United States Food and Drug Administration. Dr Brantigan has a financial interest in the Lumbar interbody carbon fiber Cage. No Financial assistance was provided from any source for this study.

Reprints: Dr Guy R. Fogel, MD, South Texas Orthopaedic and Spinal Surgery Associates, 9150 Huebner Road, San Antonio, TX 78240 (e-mail: gfogel@spinetex.com).

Copyright © 2007 by Lippincott Williams & Wilkins

Posterior lumbar interbody fusion (PLIF) was introduced by Cloward<sup>1–4</sup> more than 50 years ago. Limitations of early PLIF included inadequate compression strength of allograft bone and low fusion rates.<sup>5</sup> Carbon fiber reinforced polymer (CFRP) rectangular cages were introduced to enhance PLIF results by providing the mechanical strength to provide load-sharing during fusion and to allow the best biologic healing with autologous bone graft.<sup>6,7</sup> PLIF with CFRP cages also restores disc and neuro-foraminal height,<sup>8,9</sup> and segmental alignment including balance and lordosis.<sup>10–14</sup>

PLIF with insertion of bilateral interbody cages has been a standard treatment to predictably restore segmental alignment and balance, and obtain a successful fusion. However, occasionally only a unilateral cage may be placed because of circumstances found at the time of surgery such as limited size of the disc space, nerve root anomalies that may block access to the disc space, and limited ability to retract nerve roots due to epidural scarring of previous surgery. Because unilateral interbody fusion may be necessary in PLIF for the reasons stated above, the question is raised as to whether this will give acceptable balance, strength, and fusion results.

Recently a variation of the PLIF approach, the trans-foraminal interbody fusion (TLIF) has allowed unilateral placement of interbody cages. The TLIF approach may reduce operative time, blood loss, dural tears, and radiculopathy risks and yet provide comparable mechanical stability to the PLIF. Biomechanical studies of TLIF suggest a single interbody cage positioned in sagittal, coronal or oblique orientation provides excellent stability and stiffness.<sup>15–17</sup> Clinical and fusion results reported with TLIF are comparable with PLIF results.<sup>18–22</sup> In the TLIF reports, there is variety of type and number of implants, and type and location of bone graft material.<sup>20,23–32</sup> The rapid evolution and variety of implant and biologic technologies complicates the assessment of the TLIF technique.

This study asks if unilateral PLIF with a single cage will give acceptable results comparable with bilateral implants and to recent TLIF studies with unilateral interbody fusion. This study reports the clinical and fusion results of patients having PLIF with a unilateral approach to the disc space and compares the outcomes to historical bilateral PLIF series and recent TLIF studies.

## MATERIALS AND METHODS

The Lumbar I/F cage (DePuy Spine, Raynham, MA) is a CFRP implant made of poly-ether-ether ketone reinforced with “chopped” or short carbon fibers. The VSP (DePuy Spine, Raynham, MA) includes pedicle screws and plates. The CFRP cage and the VSP System have been previously described.<sup>33</sup>

From February 1999 to October 2003, we performed PLIF using the CFRP cages and VSP instrumentation on 425 patients in our practice. Surgical indications included disabling back and/or radicular pain refractory to conservative management with moderate to severe degenerative change, with instability and adjacent segment deterioration based on magnetic resonance imaging or discogram. During the summer of 2004, we conducted a retrospective chart review of all patients. Follow-up was achieved on 377 of 425 patients (87%) including 1-year clinical and radiographic evaluation. Although 1 year is not long enough to define an exact rate of clinical success, it is sufficient follow-up to identify complications and failed fusions.

From this large group, 26 consecutive patients were identified who had PLIF at one or more levels with a unilateral CFRP cage. Each of these patients had identical treatment to the large group including iliac crest autograft, posterolateral fusion, and bilateral pedicle screw instrumentation. The only surgical variable was that a unilateral single CFRP cage was used rather than bilateral cages. The minimum follow-up was 24 months (mean 36 mo, range 24 to 65 mo). Demographic data were recorded including age, sex, neurologic function, number and type of prior back surgeries, and diagnosis at each lumbar level. Patients were examined and data recorded before surgery, at surgery, and at postoperative intervals after surgery. Evaluations included ratings of pain, function, economic status, and medication. Patient history, sensory and motor function, tension signs, reflexes, and radiographic findings were recorded at each follow-up interval. Additional clinical data were recorded including surgery levels, operative difficulties, complications, fusion status, and reoperation or revision.

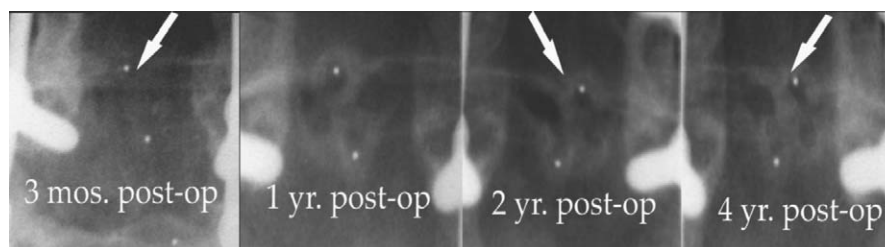
Indications for the surgery were 17 recurrent disc disease (recurrent herniation or disc space collapse with

foraminal stenosis and radiculopathy), 3 symptomatic spondylolisthesis refractory to conservative care, and 6 pseudarthroses. Two patients had significant degenerative scoliosis. Fourteen patients were revision cases with 24 prior spinal operations. In the previously operated patients, there was an average interval between the 2 surgeries of 42 months (7 mo to 7 y). There were 10 men and 16 women. The average age was 50 years (range 34 to 80 y). The insurance was workers compensation in 5 and private insurance in 21. Nine patients had a positive smoking history with an average 19-pack/year history.

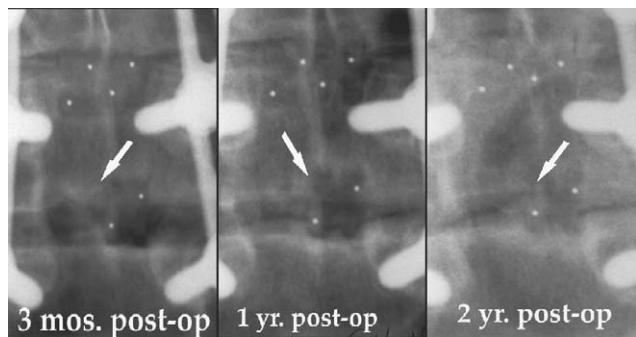
*Clinical success* was defined according to previous published literature parameters used over many years and modeled after an expanded Prolo scale.<sup>33–36</sup> The 5-point Likert scales for pain, function, economic status, and medication usage are added to a combined 4-point and 20-point scale.<sup>35</sup> This study defined a patient’s result as a clinical success when the final rating was excellent (17 to 20 points), or good (13 to 16 points), or fair (9 to 12 points) if the patient achieved a minimum improvement of 3 points or more in the combined 20-point scale.

Fusion success within the interbody space was defined by previous published parameters of radiographic fusion assessment of Brantigan and Steffee.<sup>7</sup> As recommended by Blount et al,<sup>37</sup> 2 observers evaluated the fusion from Ferguson anterior-posterior (parallel to the vertebral endplates), and lateral radiographs. A level was regarded as fused if there was radiographic evidence of bone bridging the disc space without lucency. If lucency was seen to extend across the cage, the level was considered not fused. For patients undergoing multiple-level fusion, all surgically treated segments must be fused for the patient to be considered a fusion success. Figure 1 shows a series of anterior-posterior Ferguson radiographs demonstrating progressive solid fusion. Figure 2 shows the features of a pseudarthrosis with discontinuity in the bone graft and lucency adjacent to the cage.

Statistical analysis was carried out using the  $\chi^2$  analysis. Demographics, clinical and fusion success were compared with the larger reviewed patient group, the IDE cage study,<sup>33</sup> and the available TLIF studies with a minimum 2-year follow-up<sup>20,21,29,38</sup> using  $\chi^2$  analysis. Statistical significance was defined as  $P < 0.05$ .



**FIGURE 1.** Anterior-posterior Ferguson radiographs of L4-5 taken at interval demonstrate increases in bone density within the single cage and around the cage. The contrasting radiographic densities of bone and carbon cage strut (radiodense dot in the strut) allow a comparison of increased bone density with healing of the fusion. There is no lucency between the bone and the vertebral endplates. There was fusion success at 1 year with maintained maturity through 4 years.



**FIGURE 2.** L2-4 fusion, L3-4 single cage progresses to appearance of lucencies implying pseudarthrosis with non-continuous bone across the single cage. This level was found to be healed at time of fusion exploration.

**RESULTS**

A unilateral cage was used for the indications of previous surgery with limited access to one side of the disc space in 12 (46%), not enough space in the disc space for another cage in 11 (42%), and nerve root anomaly with low position of the exiting nerve root in 3 (12%). Unilateral cages were placed at thirty lumbar levels in 26 patients. There were 8 single-level fusions with a unilateral cage; 10 with a unilateral cage at a single level in a multilevel PLIF, and 8 with multilevel unilateral cages in a multilevel PLIF. Nerve root anomalies prevented cage placement at L4-5 and L5-S1 only. Not enough space for a second cage occurred at the higher lumbar levels but not at L5-S1. Previous surgery with adhesions prohibited cage placement most frequently at L3-4 but was significant at every level. Details of the PLIF surgery are shown in Table 1.

Clinical success was achieved in 23 patients (88%). This included 3 excellent (12%), 9 good (35%), and 11 fair (42%) results. Clinical success was not achieved in 3 with poor results (12%). Table 2 correlates the clinical and fusion success of these patients.

A retropulsed cage complication occurred in 1 patient, at the L2-3 level with 2 cages in place. A cage was found to have retropulsed into the canal in the third month postoperatively. This was identified and watched. At 8 months, the patient was complaining of back pain and hip pain on the same side as the mal-positioned cage. The cage was removed and the pedicle screw instrumentation removed, and the posterior-lateral fusion was augmented with bone morphogenic protein. This case was

**TABLE 2.** Correlation of Clinical to Fusion Success

Patient No.	Clinical Success Prolo Score	Fusion Success	Final Comment
1	E	Y	Healed fusion, with ASD L2-4
2	F	Y	Pain significantly improved clinical success
3	G	Y	Healed fusion, with previous infection
4	E	Y	Healed fusion 12 mo after IR BMP
5	F	N	ASD L1-2
6	F	Y	Healed fusion with clinical success
7	G	Y	ASD L2-3
8	G	Y	ASD L1-2
9	P	Y	Healed fusion, groin pain not relieved
10	P	Y	ASD L1-2 constant pain
11	G	Y	Healed Fusion, ASD T12-L1
12	F	Y	Healed fusion, clinical success
13	F	Y	Healed fusion, with clinical success
14	F	Y	Healed fusion, ASD L3-5 continued pain
15	G	Y	ASD L2-3
16	F	Y	Healed fusion, clinical success
17	F	Y	ASD L3-4
18	G	Y	ASD L4-5, continued pain
19	G	Y	Healed Fusion, with clinical success.
20	F	Y	Healed fusion, clinical success
21	F	Y	Healed fusion, with clinical success
22	E	Y	Healed fusion, with clinical success
23	P	N	L3-4 pseudarthrosis in long fusion, chronic pain
24	G	Y	Healed fusion, with clinical success
25	F	N	Healed fusion 16 mo after 1 cage removal and BMP
26	G	Y	Hip groin pain not relieved by fusion

ASD indicates adjacent segment deterioration; BMP, bone morphogenic protein; E, excellent; F, fair; G, good; IR, implant removal; P, poor; N, no; Y, yes.

a fusion success at three years follow-up. There were no other complications such as dural tear, infection, or neurologic injury.

At the final radiographic evaluation, fusion success was achieved in all 30 unilateral-cage levels. There were no pseudarthroses, instrumentation failures, or significant subsidence at any of the unilateral cage levels. Disc space height and foraminal height were restored by the surgery and maintained at last follow-up. However, there were 3 patients with single level, 2 cage radiographic pseudarthrosis. Fusion success was then 23/26 (88%) for all

**TABLE 1.** Details of Current Fusion Levels

Lumbar Level	Total Each Level	2 Cage Levels No. (%)	1 Cage Levels No. (%)	No Cage Levels No. (%)	Levels Treated	Patients No. (%)
L1-2	2	1 (33)	1 (33)	1 (33)	1 Level	6 (23)
L2-3	10	5 (45)	5 (45)	1 (10)	2 Level	11 (42)
L3-4	14	2 (13)	12 (75)	2 (13)	3 Level	4 (15)
L4-5	14	8 (57)	6 (43)	0 (0)	4 Level	4 (15)
L5-S1	11	5 (42)	6 (50)	1 (8)	5 Level	1 (4)
Total	51	21	30	5		26

patients. The first pseudarthrosis was the L2-3 retro-pulsed cage removed at 8 months and subsequently fused on radiograph and computed tomography (CT) scan. The second was an L2-3 level persistent pseudarthrosis from an initial L2-S1 pseudarthrosis reconstruction that was explored and treated with pedicle screw implant removal and bone morphogenic protein augmentation of posterolateral fusion and subsequently was healed at last follow-up with x-rays and CT scan. The third patient had a pseudarthrosis level reported at L3-4 on CT in a L1-5 fusion for degenerative scoliosis, and did not agree with fusion exploration, accepting a fair clinical result. Table 2 correlated the clinical status with fusion success.

## DISCUSSION

The goal of lumbar interbody fusion is to relieve pain caused by neurologic compression and achievement of a stable surgical construct. Compared with posterolateral instrumented fusion, adding an interbody fusion produces a significantly stiffer construct that protects the posterior instrumentation from failure, and provides a circumferential fusion mass with an increased rate of successful fusion.<sup>7,23,33</sup> Both the PLIF and the TLIF approach offer circumferential fusion from a posterior approach.

The patients in this unilateral cage series presented with complex surgical problems that precluded the usage of the recommended bilateral interbody fusion cages. Comparison of this series with the historical investigational device exemption clinical trial (IDE) of Brantigan et al,<sup>33</sup> showed no significant difference in the indications for surgery but there was a significantly higher rate of previous surgery in this group ( $\chi^2 = 6.5202$ ,  $P$  value = 0.0107). Comparison of the clinical and fusion success showed no significant difference between this series and the IDE study. Despite the complexity of revision surgery, the outcome of the unilateral cage patients was as successful as the IDE series.

With the commonality of unilateral interbody fusion with bilateral pedicle screws and posterolateral graft, the comparison to reported TLIF studies is appropriate. Lowe et al<sup>38</sup> reported 90% fusion rate and 80% clinical success in TLIF with 2 titanium-mesh cages. Hee et al<sup>21</sup> reported 96% fusion rate with the same TLIF procedure augmented with autologous growth factors. McAfee et al<sup>19</sup> in 120 spondylolisthesis patients treated with TLIF with a unilateral CFRP cage reported a 97.5% fusion rate. Potter et al<sup>29</sup> reported 93% fusion rate and 79% clinical success with interbody structural allograft or bioabsorbable spacers. Hackenberg et al<sup>20</sup> reported 89% fusion rate and significant improvement in Oswestry disability index in TLIF with a unilateral CFRP. Molinari reported 19 active-duty military personnel were treated with 2 CFRP cages and 16 with a unilateral cage. When only a single cage was used, bone graft was inserted from a bilateral approach.<sup>27</sup> Molinari et al<sup>27</sup> reported that the results were generally good, and that patients having a

unilateral cage had equal fusion and clinical success as those having 2 cages. The fusion and clinical results of TLIF with unilateral interbody support and bone grafting were not significantly different by  $\chi^2$  analysis from this unilateral cage series.

During the design of the CFRP cages, mechanical testing assumed use of bilateral cage placement and bilateral pedicle screw fixation.<sup>14,39</sup> Biomechanical fatigue strength of 2 cages had a 2-fold safety factor over the maximal loads of daily living.<sup>40</sup> The single cage fatigue strength had a small or nonexistent safety factor over the maximal loads of daily living.<sup>40</sup> Closkey et al<sup>41</sup> in an in vitro analysis found > 30% of the vertebral endplate surface was required for load transmission across structural interbody grafts. Recent published mechanical data related to single interbody cage in TLIF found no statistical difference in initial stability and stiffness with a single cage compared with 2 cages.<sup>15-17</sup> Ames et al<sup>15</sup> in human cadavers, found no significant difference in motion between PLIF with 2 allograft bone spacers and TLIF with a single spacer as long as there were bilateral pedicle screws. Chen et al<sup>16</sup> in a porcine model found unilateral cage and unilateral pedicle screws had similar stability to the unilateral cage with bilateral pedicle screws. Kettler et al<sup>17</sup> in a human cadaver found a unilateral cage is as stable as bilateral cages. Position of the graft did not change the stiffness or stability.<sup>15,42</sup> Ames et al<sup>15</sup> varied the position of the unilateral graft between the anterior and middle column without diminution of the stability or stiffness of the construct. Harris et al<sup>42</sup> in a human cadaver study placed an oblique single CFRP cage, and found the addition of bilateral pedicle screws matched the flexibility of an intact motion segment. Heth et al<sup>43</sup> compared anterior and transverse placement of threaded cylindrical cages and found no difference in stability with transverse positioned cages. Wang et al<sup>44</sup> in human cadavers compared sagittal versus oblique placement of cylindrical cages and found any differences between cage position was normalized with bilateral pedicle screw fixation. Several key points are made by these studies. A unilateral cage is as stable and stiff as bilateral cages. Cage position does not decrease the stability of the construct. All constructs are improved by bilateral pedicle screw fixation.

Bone grafting of the available surface area of the disc space is important for fusion success. Prolo<sup>36</sup> found successful fusion filled 77% of the available disc space with bone. A clinical study using CT scan to demonstrate disc removal showed more than 56% of the cross-sectional area of the endplate could be cleared from a unilateral TLIF approach.<sup>45</sup> The surface area of exposed bone graft in a single CFRP cage is 138 mm<sup>2</sup> and the surface area of a typical L5 lumbar endplate is 1259 mm<sup>2</sup>. A single CFRP cage will fill only 10% of the endplate.<sup>40</sup> Additional bone grafting to fill all available surface area is recommended. Placement of additional bone graft around the single cage may account for the undiminished high rate of fusion success in this series.

A shortcoming of this study is that a small population will result in poor specificity or underestimation of the actual pseudarthrosis rate. To improve the statistical power of the study would require a large number of patients that may be impractical. This study demonstrates successful fusion and clinical results when the patient selection criteria are expanded to include complex revision surgical problems. The results of this study support the use of a unilateral interbody cage combined with bilateral posteriolateral fusion and pedicle screws. A prospective randomized trial comparing unilateral with bilateral CFRP cages is warranted. The authors emphasize that when a fusion is done with an unilateral approach to the disc space, it is particularly important for the surgeon to pack additional bone in the disc space around the cage.

### CONCLUSIONS

Fusion and clinical success rates are not diminished by the use of a unilateral CFRP cage rather than the recommended 2 cages. Clinical success with the unilateral single cages was not statistically different from the clinical success rates of the IDE study. Fusion success was achieved in 100% of 30 single cage levels and 23 of 26 patients (89%) at all fusion levels. Mechanical failure did not occur with the single cage. A single cage with bilateral pedicle screws provides adequate alignment, balance, and mechanical stability, and allows the maximal amount of autologous graft to fill the disc space.

### REFERENCES

- Cloward RB. The treatment of ruptured lumbar intervertebral discs by vertebral body fusion. I. Indications, operative technique, after care. *J Neurosurg.* 1953;10:154-168.
- Cloward RB. Lesions of the intervertebral disks and their treatment by interbody fusion methods. The painful disk. *Clin Orthop.* 1963;27:51-77.
- Cloward RB. Spondylolisthesis: treatment by laminectomy and posterior interbody fusion. *Clin Orthop.* 1981;74-82.
- Cloward RB. Posterior lumbar interbody fusion updated. *Clin Orthop.* 1985;16-19.
- Brantigan JW, Cunningham BW, Warden K, et al. Compression strength of donor bone for posterior lumbar interbody fusion. *Spine.* 1993;18:1213-1221.
- Brantigan JW. Pseudarthrosis rate after allograft posterior lumbar interbody fusion with pedicle screw and plate fixation. *Spine.* 1994;19:1271-1279; Discussion 1280.
- Brantigan JW, Steffee AD. A carbon fiber implant to aid interbody lumbar fusion. Two-year clinical results in the first 26 patients. *Spine.* 1993;18:2106-2107.
- Tullberg T, Brandt B, Rydberg J, et al. Fusion rate after posterior lumbar interbody fusion with carbon fiber implant: 1-year follow-up of 51 patients. *Eur Spine J.* 1996;5:178-182.
- Hashimoto T, Shigenobu K, Kanayama M, et al. Clinical results of single-level posterior lumbar interbody fusion using the Brantigan I/F carbon cage filled with a mixture of local morselized bone and bioactive ceramic granules. *Spine.* 2002;27:258-262.
- Sears W. Posterior lumbar interbody fusion for lytic spondylolisthesis: restoration of sagittal balance using insert-and-rotate interbody spacers. *Spine J.* 2005;5:161-169.
- Molinari RW, Bridwell KH, Lenke LG, et al. Anterior column support in surgery for high-grade, isthmic spondylolisthesis. *Clin Orthop Relat Res.* 2002;109-120.
- Kwon BK, Berta S, Daffner SD, et al. Radiographic analysis of transforaminal lumbar interbody fusion for the treatment of adult isthmic spondylolisthesis. *J Spinal Disord Tech.* 2003;16:469-476.
- Brantigan JW, Neidre A. Achievement of normal sagittal plane alignment using a wedged carbon fiber reinforced polymer fusion cage in treatment of spondylolisthesis. *Spine J.* 2003;3:86-196.
- Brantigan JW, Steffee AD, Geiger JM. A carbon fiber implant to aid interbody lumbar fusion. Mechanical testing. *Spine.* 1991;16(suppl 6):S277-S282.
- Ames CP, Acosta FL Jr, Chi J, et al. Biomechanical comparison of posterior lumbar interbody fusion and transforaminal lumbar interbody fusion performed at 1 and 2 levels. *Spine.* 2005;30:E562-E566.
- Chen HH, Cheung HH, Wang WK, et al. Biomechanical analysis of unilateral fixation with interbody cages. *Spine.* 2005;30:E92-E96.
- Kettler A, Schmoelz W, Kast E, et al. In vitro stabilizing effect of a transforaminal compared with two posterior lumbar interbody fusion cages. *Spine.* 2005;30:E665-E670.
- Lowe TG, Tahernia AD. Unilateral transforaminal posterior lumbar interbody fusion. *Clin Orthop Relat Res.* 2002;64-72.
- McAfee PC, Devine JG, Chapat CD, et al. The indications for interbody fusion cages in the treatment of spondylolisthesis: analysis of 120 cases. *Spine.* 2005;30:S60-S65.
- Hackenberg L, Halm H, Bullmann V, et al. Transforaminal lumbar interbody fusion: a safe technique with satisfactory three to five year results. *Eur Spine J.* 2005;14:551-558.
- Hee HT, Majd ME, Holt RT, et al. Do autologous growth factors enhance transforaminal lumbar interbody fusion? *Eur Spine J.* 2003;12:400-407.
- Zhao J, Wang X, Hou T, et al. One versus two BAK fusion cages in posterior lumbar interbody fusion to L4-L5 degenerative spondylolisthesis: a randomized, controlled prospective study in 25 patients with minimum two-year follow-up. *Spine.* 2002;27:2753-2757.
- Wang JC, Mummaneni PV, Haid RW. Current treatment strategies for the painful lumbar motion segment: posterolateral fusion versus interbody fusion. *Spine.* 2005;30(suppl 16):S33-S43.
- Coe JD, Vaccaro AR. Instrumented transforaminal lumbar interbody fusion with bioresorbable polymer implants and iliac crest autograft. *Spine.* 2005;30(suppl 17):S76-S83.
- Harms J, Jeszszky D, Stolze D. True spondylolisthesis reduction and more segmental fusion in spondylolisthesis. In: Bridwell KH, DeWald RL, eds. *Textbook of Spinal Surgery.* Philadelphia: Lippincott-Raven; 1997:1337-1347.
- Humphreys SC, Hodges SD, Patwardhan AG, et al. Comparison of posterior and transforaminal approaches to lumbar interbody fusion. *Spine.* 2001;26:567-571.
- Molinari RW, Sloboda J, Johnstone FL. Are 2 cages needed with instrumented PLIF? A comparison of 1 versus 2 interbody cages in a military population. *Am J Orthop.* 2003;32:337-343; Discussion 343.
- Mummaneni PV, Rodts GE Jr. The mini-open transforaminal lumbar interbody fusion. *Neurosurgery.* 2005;57(suppl 4):256-261; Discussion 256-261.
- Potter BK, Freedman BA, Verwiebe EG, et al. Transforaminal lumbar interbody fusion: clinical and radiographic results and complications in 100 consecutive patients. *J Spinal Disord Tech.* 2005;18:337-346.
- Rivet DJ, Jeck D, Brennan J, et al. Clinical outcomes and complications associated with pedicle screw fixation-augmented lumbar interbody fusion. *J Neurosurg Spine.* 2004;1:261-266.
- Salehi SA, Tawk R, Ganju A, et al. Transforaminal lumbar interbody fusion: surgical technique and results in 24 patients. *Neurosurgery.* 2004;54:368-374; Discussion 374.
- Schwender JD, Holly LT, Rouben DP, et al. Minimally invasive transforaminal lumbar interbody fusion (TLIF): technical feasibility and initial results. *J Spinal Disord Tech.* 2005;18(suppl):S1-S6.
- Brantigan JW, Steffee AD, Lewis ML, et al. Lumbar interbody fusion using the Brantigan I/F cage for posterior lumbar interbody fusion and the variable pedicle screw placement system: two-year results from a Food and Drug Administration investigational device exemption clinical trial. *Spine.* 2000;25:1437-1446.

34. Brantigan JW, Neidre A, Toohey JS. The lumbar I/F cage for posterior lumbar interbody fusion with the Variable Screw Placement System: 10-year results of a food and drug administration clinical trial. *Spine J*. 2004;4:681–688.
35. Stromberg L, Toohey JS, Neidre A, et al. Complications and surgical considerations in posterior lumbar interbody fusion with carbon fiber interbody cages and Steffee pedicle screws and plates. *Orthopedics*. 2003;26:1039–1043.
36. Prolo DJ, Oklund SA, Butcher M. Toward uniformity in evaluating results of lumbar spine operations. A paradigm applied to posterior lumbar interbody fusions. *Spine*. 1986;11:601–606.
37. Blount KJ, Krompinger WJ, Maljanian R, et al. Moving toward a standard for spinal fusion outcomes assessment. *J Spinal Disord Tech*. 2002;15:16–23.
38. Lowe TG, Tahernia AD, O'Brien MF, et al. Unilateral transforaminal posterior lumbar interbody fusion (TLIF): indications, technique, and 2-year results. *J Spinal Disord Tech*. 2002;15:31–38.
39. Brantigan JW, McAfee PC, Cunningham BW, et al. Interbody lumbar fusion using a carbon fiber cage implant versus allograft bone. An investigational study in the Spanish goat. *Spine*. 1994;19:1436–1444.
40. Serhan H. Presentation of mechanical testing of the Brantigan cage. In: *The Orthopaedics and Rehabilitation Devices Advisory Panel Meeting of the Department of Health and Human Services, Public Health Service, Food and Drug Administration*. Maryland: Bethesda; 1997.
41. Closkey RF, Parsons JR, Lee CK, et al. Mechanics of interbody spinal fusion. Analysis of critical bone graft area. *Spine*. 1993;18:1011–1015.
42. Harris BM, Hilibrand AS, Savas PE, et al. Transforaminal lumbar interbody fusion: the effect of various instrumentation techniques on the flexibility of the lumbar spine. *Spine*. 2004;29:E65–E70.
43. Heth JA, Hitchon PW, Goel VK, et al. A biomechanical comparison between anterior and transverse interbody fusion cages. *Spine*. 2001;26:E261–E267.
44. Wang ST, Goel VK, Fu CY, et al. Posterior instrumentation reduces differences in spine stability as a result of different cage orientations: an in vitro study. *Spine*. 2005;30:62–67.
45. Javernick MA, Kuklo TR, Polly DW Jr. Transforaminal lumbar interbody fusion: unilateral versus bilateral disk removal—an in vivo study. *Am J Orthop*. 2003;32:344–348; Discussion 348.