

# Outcomes of L1–L2 posterior lumbar interbody fusion with the Lumbar I/F cage and the variable screw placement system: reporting unexpected poor fusion results at L1–L2

Guy R. Fogel, MD\*, John S. Toohey, MD, Arvo Neidre, MD, John W. Brantigan, MD

South Texas Orthopaedic and Spinal Surgery Associates, 9150 Huebner Road, San Antonio TX 78240, USA

Received 1 July 2005; accepted 30 September 2005

## Abstract

**BACKGROUND CONTEXT:** Posterior lumbar interbody fusion (PLIF) was introduced 50 years ago. The Lumbar I/F cage (DePuy Spine, Raynham, MA) was designed to enhance PLIF results. PLIF with the Lumbar I/F cage and posterior Variable Screw Placement System (VSP) has increased the success of fusion to nearly 100% at the four lowest lumbar levels, L2–L3 through L5–S1. Less commonly, PLIF is indicated for the L1–L2 level. Clinical-results of Lumbar I/F cage fusion and VSP at L1–L2 have-not been reported.

**PURPOSE:** The purpose of this study is to report the functional outcomes, fusion rate, and complications related to PLIF with Lumbar I/F cage and VSP of L1–L2

**STUDY DESIGN/SETTING:** The setting is a retrospective, single-arm cohort study of consecutive PLIF surgical patients at a single center.

**PATIENT SAMPLE:** A review of 373 of 425 patients who underwent PLIF with Lumbar I/F cage and VSP from 1999 to 2002 identified 12 patients who had PLIF with Lumbar I/F cage and VSP at L1–L2. Mean follow-up was 31 months (range 12–65 months).

**OUTCOME MEASURES:** Clinical success was determined with a modified Prolo score evaluating pain, function, medication usage and economic status. Fusion success, determined by evaluation of plain radiographs, was defined by continuous bone bridging the fusion area with no lucencies.

**METHODS:** The 12 patients were evaluated for clinical success and/fusion success at last follow-up. These results were compared with the results of the 373 patients reviewed, and historical groups of the original Investigational Device Exemption study and the 10-year follow-up study.

**RESULTS:** Previous surgery was reported by 10 of 12 patients, with an average symptom-free period of 3 years after previous fusion and before presentation with severe symptomatology necessitating further surgery at L1–L2. Seven patients had clinical success (59%), and five patients were clinically unsuccessful (41%). This included zero excellent, 2 of 12 (15%) good, 5 of 12 (42%) fair, and 5 of 12 (42%) poor results. Fusion was successful in seven (58%) and failed in five patients (42%). Three failed fusions were associated with L1–L2 subsidence. Two patients required further revision for non-union.

**CONCLUSIONS:** In 12 patients with L1–L2 fusion, we report an unexpected high rate of failed fusion and poor clinical outcome. © 2006 Elsevier Inc. All rights reserved.

## Keywords:

PLIF; Interbody fusion orthosis; Cage; Pedicle screw; Degenerative disc diseases; Spinal fusion/instrumentation/ methods; Treatment outcome

Device status: The Lumbar I/F cage and the VSP Spinal Fixation System are approved by the US Food and Drug Administration. Dr. Brantigan has a financial interest in the Lumbar I/F cage. No financial assistance was provided from any source for this study.

\* Corresponding author. South Texas Orthopaedic and Spinal Surgery Associates, 9150 Huebner Road, Suite 350, San Antonio, TX 78240. Tel.: (210) 561-7234; fax: (210) 561-7240.

E-mail address: [gfogel@spinetex.com](mailto:gfogel@spinetex.com) (G.R. Fogel)

## Introduction

Posterior lumbar interbody fusion (PLIF) was introduced by Cloward [1–4] more than 50 years ago. Limitations of PLIF included inadequate compression strength of allograft bone [5] and low fusion rates [6]. The Lumbar I/F cage (DePuy Spine, Raynham, MA) was designed to enhance posterior lumbar interbody fusion results by

providing the mechanical strength to provide load-sharing during fusion and to allow the best biological healing with autologous bone graft [7].

In an Investigational Device Exemption (IDE) study of the Lumbar I/F cage, fusion success was reported in 176 of 178 patients (98.9%) [8]. Almost half of the study cases were two-level procedures. Less than 10% were three- or four-level procedures. The high fusion success was undiminished over multiple fusion levels including 100% of the three- and four-level fusions. Based on this study, the Lumbar I/F cage was approved by the Food and Drug Administration for treatment of degenerative disc disease at one or two contiguous levels from L2 to the sacrum, accompanied by posterolateral fusion and pedicle screw fixation using the Variable Screw Placement (VSP) Spinal System.

The L1–L2 level was excluded from the study protocol and from the Food and Drug Administration approval because of the low frequency of isolated degenerative disc disease at this level. The approval was limited to two levels because of the small number of three- and four-level procedures in the study. Nevertheless, some patients develop symptomatic degenerative disc disease at the L1–L2 level. The purpose of this retrospective review is to report the functional outcomes, fusion rate, and complications related to PLIF with Lumbar I/F cage and VSP of L1–L2.

## Materials and methods

### *Description of the Lumbar I/F cage*

The Lumbar I/F cage is manufactured from poly-ether-ether ketone reinforced with “chopped” or short carbon fibers. The cage is filled with autologous bone and placed in a disc space channel. This allows bone fusion from end plate to end plate across the bone graft within the cage. The cage material is one-tenth the stiffness as compared with metal and minimizes stress shielding of the bone graft [8]. Because the cages are radiolucent, bridging bone can be accurately assessed by plain radiographs.

### *Description of the Variable Screw Placement System (VSP)*

The VSP (DePuy Spine, Raynham, MA) includes pedicle screws and plates. The screw has a cancellous thread ending in an integral nut, above which a machine thread with tapered and locking nuts allows the screw to be anchored securely to the plate [8].

### *Description of the operation*

In the standard PLIF operation, the extent of the required laminectomy should expose the entire space between the medial walls of the pedicles. The superior one-third of the lamina should be preserved to maintain continuity of

ligament structures above the fusion level. At L1–L2, because of increased risk of neurological injury to the conus medullaris, a more lateral approach was used, essentially a transforaminal lumbar interbody fusion. A spreader is placed in the disc space and used to distract the disc space on each side to normal disc height or to the elastic limit of the annulus. A “working plate” is tightened down over the pedicle screws on one side to hold the distraction. In contrast to PLIF at the lower levels, it is not generally possible to use bilateral working plates. Next, a round reamer is used to prepare a round hole in the disc space on the opposite side. The goal of reaming and broaching is merely to flatten the end plate, not to cut a deep channel. Therefore, for placement of a 9-mm cage, the disc space should be distracted to 9 mm. The 9-mm reamer should be used, followed by the 9-mm broaches. The “guided broach” follows the round channel and makes it square. The “final broach” follows the previous channel and squares the bottom most portion of the channel. The final broach should be held with fingertip force only and allowed to follow the previous channel. A “false channel” is created if the final broach is placed in a different direction than the guided broach, thus creating an excessively large channel that will predispose to a loose-fitting cage and pseudarthrosis. We recommend if there is any question of the correct direction of the final broach that the final broach merely be omitted.

### *Clinical study design*

From February 1999 to October 2003, we performed PLIF using the Lumbar I/F cage with VSP pedicle screw fixation on 425 patients in our practice. During the summer of 2004, we conducted a retrospective chart review of all patients. We had a minimum of 1 year of full clinical and radiographic data on 377 of 425 patients (87%). Although 1 year is not long enough to define an exact rate of clinical success, it is sufficient follow-up to identify complications and failed fusions. From this group we identified 12 patients who had received PLIF at the L1–L2 level. The mean follow-up was 31 months (range 12–65 months). All 425 operated patients had disabling back and/or radicular pain refractory to conservative management with moderate to severe degenerative change, with instability and adjacent segment deterioration based on flexion-extension radiographs, magnetic resonance imaging (MRI), or discogram. In the subset of 12 L1–L2 patients, 10 patients had 25 prior spinal operations (average 2.5). In the previously operated patients, there was an average symptom-free interval of 3 years (1–7 years), followed by onset of significant and severe symptoms correlating with imaging identifying L1–L2 as the source of the new symptoms. At the L1–L2 level, nine had preoperative radiographic adjacent segment degeneration with or without stenosis, and three had herniated degenerative discs causing stenosis in the presence of degenerative flexion-extension or rotational instability.

Of the 12 L1–L2 patients, there were three men and nine women. Average age was 44 years (range 34 to 80). Insurance was workers' compensation in four and private insurance in eight. Three patients had positive smoking history with an average 21-pack/year histories.

*Clinical success* was defined according to previous published literature parameters used over many years and modeled after an expanded Prolo Scale [8–11]. The 5-point Likert scales for pain, function, economic status, and medication usage are added to a combined 4- and 20-point scale as used for the IDE study of the Lumbar I/F cage [8]. This study defined a patient's result as a clinical success when the final rating was excellent (17 to 20 points) or good (13 to 16 points), or fair (9 to 12 points) with a minimum improvement of three points or more in the combined 20-point scale.

#### Fusion status

Fusion status was recorded for each surgically treated segment at each follow-up interval. *Fusion healing* was defined by previously published literature parameters [8–10]. *Fusion success* was defined as radiographic evidence of bone bridging the disc space within the cages, without evidence of lucency across the cage. If lucency was seen to extend across the cage, the level was considered not fused. For patients undergoing multiple-level fusion, all surgically

treated segments must be fused for the patient to be considered a fusion success.

#### Sagittal plane alignment

The sagittal alignment is approximately 5 degrees kyphosis at the thoracolumbar junction [12]. After surgery, progressive kyphosis may impair the final result. The radiographic criteria of proximal junctional kyphosis was adapted from Yang and Chen [13] and defined as greater than 10 degrees progression in the proximal segment kyphotic angle from preoperative to last follow-up radiograph. Proximal segment kyphosis was measured from T11–T12 to L1–L2 disc spaces on the current radiographs. This measurement included two disc spaces and the T12 vertebral body. The angle was measured by the method of Cobb [14]. Measurements were made on the preoperative and last follow-up lateral radiographs. Additional Cobb angle measurement was made of the L1–L2 disc space on preoperative and last follow-up radiographs.

## Results

#### Clinical success

Clinical success was achieved in 7 of 12 patients (59%). This included 2 (17%) Good and 5 (42%) Fair results. Clinical success was not achieved in the other 5 (42%) with

Table 1  
Success parameters, prior and further surgeries

Patient	Clinical success	Fusion success	Comment	# Prior surgery	Previous operated levels	Further surgery
1	Y	Y	Fused radiographically. Continued pain with limitations.	5	L3–S1 PLIF	None
2	N	Y	Fused radiographically, T12–L1 ASD with instability.	2	L3–L5 PLIF	None
3	N	Y	Fused radiographically at every level with continued pain.	2	L2–L4 PLIF	L4–S1 PLIF
4	Y	Y	Healed fusion at time of exploration effusion.	1	L4–L5 PLIF	None
5	Y	Y	Fused radiographically with mild pain and limitations.	2	L2–L4 PLIF	I.R. L1–L2, LI screw loose, fusion healed
6	N	N	Reinjury 6 months post-op. Recurrent pain.	0	None	None
7	N	N	Fused radiographically ASD T12–L1 continued pain.	5	L2–S1 PLIF	None
8	Y	N	Pseudarthrosis twice at exploration. Treated with re-instrumentation and BMP, then IR with BMP.	3	L3–S1 PLIF	Revision PLF BMP and screws x1, IR BMP BMP x1
9	Y	N	Pseudarthrosis at exploration. IR with BMP.	2	L2–L5 PLIF	IR BMP PLF
10	Y	N	Pseudarthrosis radiographically with L1–L2 subsidence.	2	L4–L5 PLIF	None
11	N	Y	Fused radiographically with continued pain.	0	None	L2–L4 PLIF
12	Y	Y	Fused radiographically, with asymptomatic L2–L3 stenosis.	1	L4–L5 PLIF	None

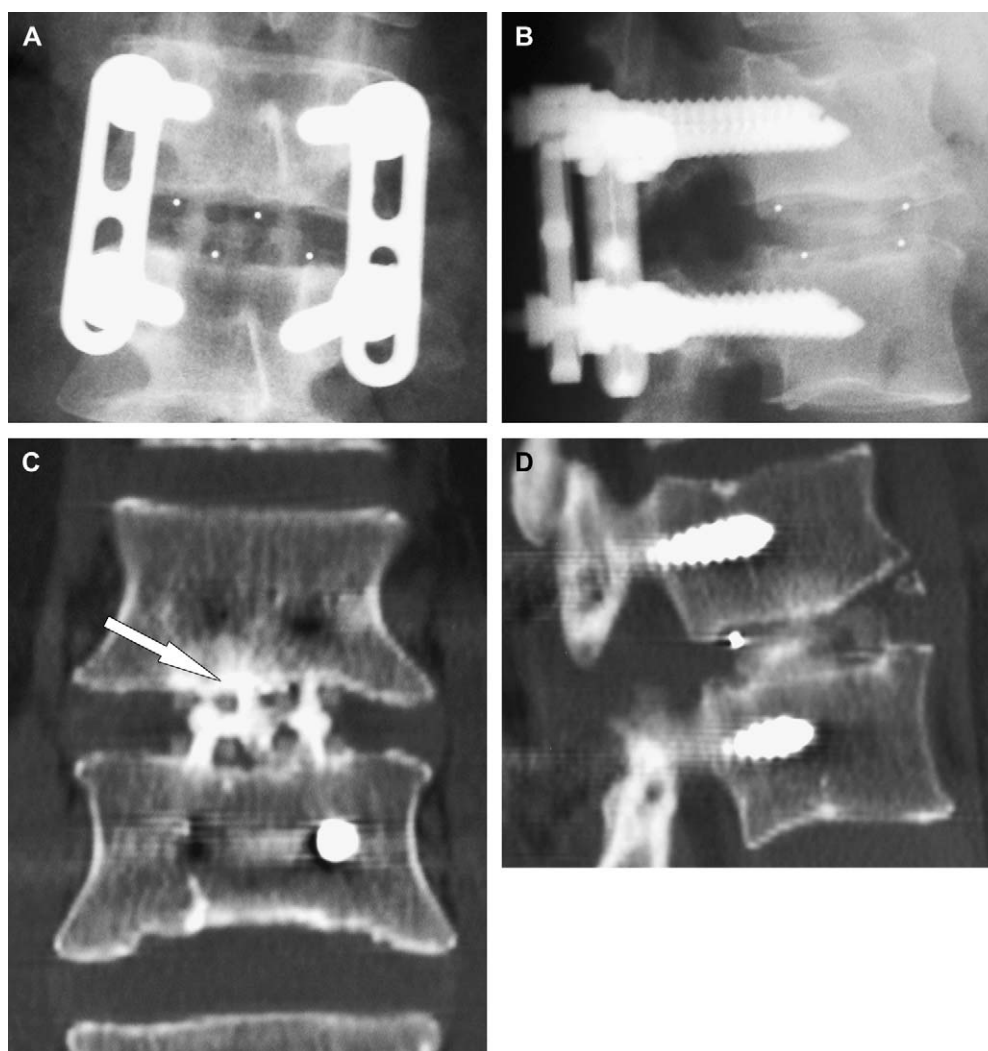
ASD=adjacent segmental degeneration; BMP=bone morphogenic protein; IR=Implant removal of pedicle screws and plates; N=no; PLF=posterolateral fusion; Y=yes.

Poor results. Both patients without previous surgery were clinically unsuccessful. **Table 1** lists the clinical status of these patients at final follow-up.

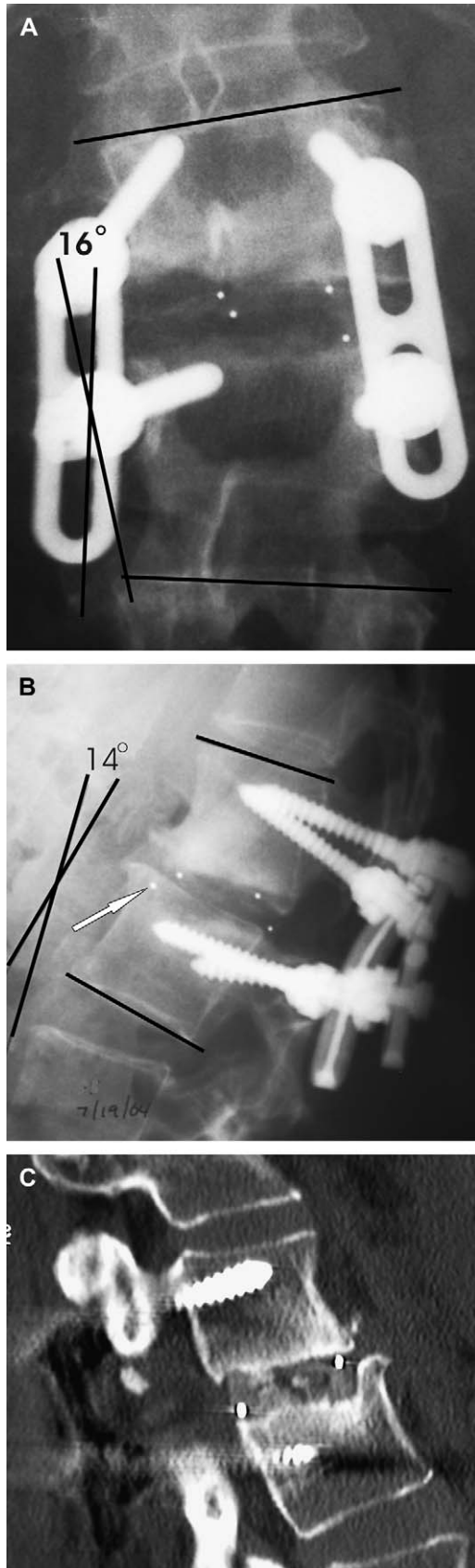
#### *Fusion success*

Fusion success was achieved in 7 (59%) (**Table 1** and **Fig. 1**), and was unsuccessful in 5 (42%) patients. Fusion was successful in two of the three patients who smoked, and unsuccessful in one. The failures were not limited to patients having a long fusion ending at L1. Of the five patients having L1–L2 fused with a nonfused adjacent L2–L3 segment, two patients had fusion failure and three were unsuccessful clinically with poor Prolo scores. Failed fusion was associated with subsidence in three, pedicle screw

loosening in two, and in one 34-year-old woman, a single cage retropulsed 5 mm without clinical neurologic symptoms. This patient had an isolated L1–L2 PLIF, without previous surgery. One of the two cages retropulsed into the spinal canal, causing back pain without neurologic loss. The device failure led to an unsuccessful fusion. The other patient without previous PLIF had L1–L2 and L4–S1 PLIF with successful fusion of both levels (**Fig. 1**). **Table 1** correlates the clinical status with fusion success. **Figure 1** is an example of a healed fusion. **Figure 2** is an example of a failed fusion with subsidence of the cages causing increased kyphosis and lateral tilt through the disc space. **Figure 3** demonstrated computed tomographic (CT) evidence of nonunion above a long fusion. **Figure 4** shows CT evidence of nonunion of L1–L2, with the adjacent L2–L3 level never treated.



**Fig. 1.** (A) Patient 4 is a 37-year-old man with healed L1–L2 fusion anterior posterior radiograph 1 year after posterior lumbar interbody cage fusion L1–L2. Bone density is demonstrated within the fusion cage and spanning the disc space between the end plates. There is increased bone density suggesting completion of interbody fusion healing. There is no lucency between the bone and the vertebral end plates. (B) Lateral radiograph 1 year after posterior lumbar interbody cage fusion L1–L2. Increased bone density is demonstrated across the fusion cage between the end plates, implying complete fusion. (C) Coronal computed tomographic scan through the interbody cages, with arrow demonstrating bridging bone through the cage spanning the disc space and connecting the end plates. (D) Sagittal computed tomographic scan through an interbody cage: arrow demonstrating increased bone density spanning the disc space continuous with the end plates.



### Cages used in L1–L2 fusion

Ten patients had two cages placed at the L1–L2 level. The other two patients had a single cage placed at L1–L2 (9×9×25 mm). The reason given for a single cage was the limited space in the disc space for two cages, and in one report, concern about retraction of the dura with the conus medullaris near-by. In the first single-cage case, Healos (Depuy Spine), an osteoconductive matrix, was used to fill the other side of the disc space. In the second case, a trans-foraminal approach was used to place a single cage obliquely across the disc space. In 11 patients, the cages were 9×9×25 mm length. One patient had two 9×11×25 mm cages. A total of 22 interbody cages at L1–L2 were used. All levels were supported with bilateral pedicle screws and VSP plates.

### Complications

In one patient, an epidural hematoma with acute cauda equina syndrome occurred immediately after L1–L2 surgery. The hematoma was drained immediately with complete resolution of all symptoms. Another had loosening of the pedicle screw fixation, with subsidence and kyphosis across the L1–L2 segment. This patient is using an electromagnetic bone stimulation device to encourage bone fusion healing.

### Further surgery

Five patients had further surgery after the L1–L2 fusion at an average of 18 months (range 14–26 months), as reported in Table 1.

### Sagittal plane alignment

There was no preoperative proximal segmental T11–L1 kyphosis above the L1–L2 fusion. There was no proximal segmental T11–L1 kyphosis at last follow-up. Two patients developed L1–L2 segmental kyphosis greater than 8 degrees associated with radiographic subsidence of one or both of the interbody cages through the L2 cephalic end plate. One patient with 3 degrees angulation did not have

←  
 Fig. 2. (A) Patient 10 is a 45-year-old woman at 1 year after L1–L2 PLIF. Anterior-posterior radiograph 1 year after posterior lumbar interbody cage fusion L1–L2 shows a 16-degree lateral tilt deformity through the disc space, with incomplete or blocked areas of bone density within the fusion cage. (B) Lateral radiograph 1 year after posterior lumbar interbody cage fusion L1–L2. The arrow demonstrates subsidence of the disc space with intrusion of the interbody cage through the cephalic end plate of L2. There is a resultant 14-degree kyphosis at L1–L2. There is nonunion of the interbody fusion at L1–L2. (C) Sagittal helical thin-cut computed tomographic scan through an interbody cage at L1–L2. The arrow demonstrates subsidence of the cage into the L2 cephalic end plate. There is incomplete bridging of the bone density across the disc space. A lucency extends across the disc space, implying incomplete healing of the disc space interbody cage fusion.

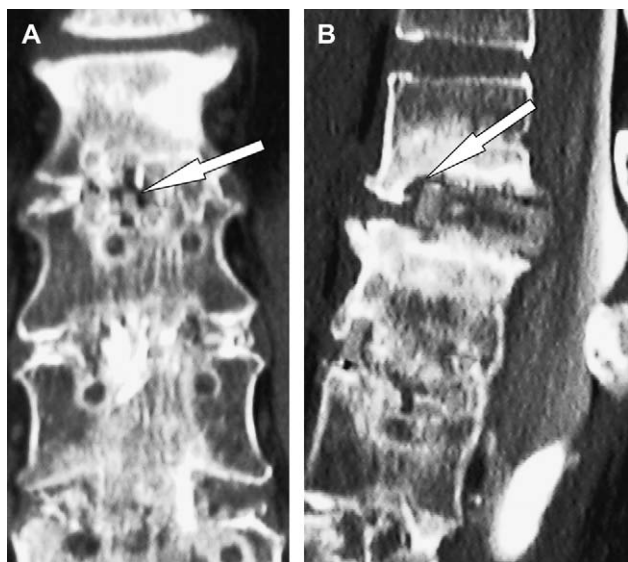

Fig. 3. (A) Patient 9, a 48-year-old woman with nonunion L1–L2 above previously healed L2–L5 posterior lumbar interbody fusion. Computed tomography 12 months after L1–L2 implant removal and bone morphogenic protein augmentation of posterior-lateral fusion; computed tomographic coronal reconstruction of L1–L2: an arrow demonstrates a lucency running horizontally through the fusion mass within the interbody cage. (B) Computed tomographic sagittal reconstruction: arrow shows lucency around a cage with 2 mm retropulsion of the cage into the canal.

identified subsidence. The three patients with increased Cobb angle measurement across the L1–L2 disc space did have failed fusions.

## Discussion

### Outcome measures

At the time of the original Brantigan Lumbar I/F cage IDE in 1990, there was little agreement regarding optimum outcome measures in a spinal fusion study. To our knowledge, a thorough examination of the statistical validity of the Prolo Scale has not been undertaken. However, the Prolo Score has been widely accepted and is used in this report to maintain continuity with the original IDE and the 10-year follow-up of the Lumbar I/F cages. We believe the Prolo Scale produces results that may be compared with literature reports of outcomes over many years [8,9].

### Previous surgery

Ten of the 12 patients had previous PLIF surgery (average 2.5 surgeries/patient). In these 10 patients, there was a 3-year average symptom-free time before presentation with severe symptoms requiring surgical treatment at the adjacent L1–L2 level. In patients with prior surgery, diagnosis was based on progressive MRI changes over time or by positive concordant pain reproduction on discogram. In patients without adjacent fusion, diagnosis was based on

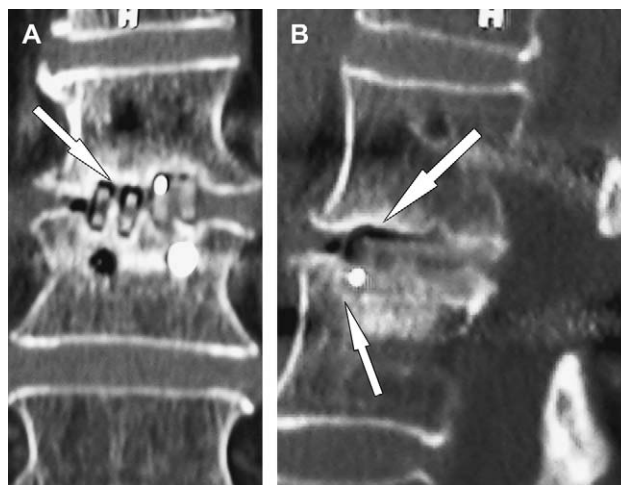


Fig. 4. (A) Patient 8, a 73-year-old woman with previous L3–S1 healed fusion, has nonunion of L1–L2. Coronal computed tomographic reconstruction reveals lucency surrounding both interbody cages at L1–L2. (B) Sagittal computed tomographic reconstruction: superior arrow demonstrates lucency around the cage, and inferior arrow shows subsidence into L2 body. Metallic dot in the disc space is the cage position marker.

MRI findings with positive discogram. The rate of previous surgery of this group is not significantly different than the original IDE Lumbar I/F cage study wherein there were 326 surgeries in 170 patients reported (average 1.9 surgeries/patient) [8] (chi-square=0.2662,  $p=.6059$ ).

### Clinical success

The Lumbar I/F cages IDE study reported clinical success in 79 of 91 (86.8%) [8]. In the larger clinical series from our group, clinical success was achieved in 285 of 345 (82%) of non-L1–L2 patients. When the clinical results of our larger clinical series are compared with the IDE results using the chi-square statistic, clinical success rates are not statistically different (chi-square=.555,  $p=.4563$ ). When the clinical results of the L1–L2 group are compared with the larger clinical series from our group using the chi-square statistic, clinical success rates at L1–L2 are one-half of the expected success at the lower lumbar levels of PLIF (chi-square=4.588,  $p=.0322$ ).

### Fusion success

The Lumbar I/F cage IDE study reported fusion success in 176 of 178 (98.9%) [8]. In the larger clinical series from our group, fusion success was achieved in 321 of 326 non-L1–L2 patients (98%). When the fusion results of our larger series are compared with the IDE results using the chi-square statistic, the fusion rates are not statistically different (chi-square=0.1414,  $p=.7069$ ). When the fusion results of the L1–L2 group are compared with the larger clinical series from our group using the chi-square statistic, L1–L2 fusion rates are 60% lower (chi-square=64.9297,  $p<.0001$ ).

### *Sagittal plane alignment*

The development of junctional kyphosis above a short segmental fusion for thoracolumbar scoliosis or fracture management is not well understood. An increase in kyphosis may give a displeasing cosmetic result, and may result in revision of the fusion [15–17]. Yang and Chen found in five patients with preoperative junctional kyphosis of more than 10 degrees, four of five developed increased junctional kyphosis [13]. In this series, no junctional kyphosis was identified preoperatively, and no increase in kyphosis was found at last follow-up. Isolated L1–L2 angulation was associated with subsidence of the interbody cages in two failed fusions.

### *Biomechanics*

Deformity and trauma surgeons have long recommended that a fusion should not end at L1 because of an excessively high rate of mechanical stress and failure at the thoracolumbar junction. Instead, two thoracic levels should be included in the instrumentation and fusion. We had expected that the extra stability afforded by anterior cage placement with pedicle screw fixation would compensate for the added stresses at this level. This expectation was not realized. The failures were not limited to patients having a long fusion ending at L1. Of the five patients having L1–L2 fused with a nonfused adjacent L2–L3 segment, two patients had fusion failure, and three were unsuccessful clinically with poor Prolo scores. None of the five has required further surgery, but revision has been recommended in both fusion failures.

### **Conclusions**

In this small group of L1–L2 posterior lumbar interbody cage fusion with VSP patients, there was a high rate of failed fusion, and poor clinical success. The failures were not limited to patients having a long fusion ending at L1. This study reports an unexpectedly high failure rate at L1–L2 but does not provide a solution for those patients requiring treatment at this level.

### **References**

- [1] Cloward RB. The treatment of ruptured lumbar intervertebral discs by vertebral body fusion. I. Indications, operative technique, after care. *J Neurosurg* 1953;10:154–68.
- [2] Cloward RB. Lesions of the intervertebral disks and their treatment by interbody fusion methods. The painful disk. *Clin Orthop* 1963;27:51–77.
- [3] Cloward RB. Spondylolisthesis: treatment by laminectomy and posterior interbody fusion. *Clin Orthop* 1981;154:74–82.
- [4] Cloward RB. Posterior lumbar interbody fusion updated. *Clin Orthop* 1985;193:16–9.
- [5] Brantigan JW, Cunningham BW, Warden K, McAfee PC, Steffee AD. Compression strength of donor bone for posterior lumbar interbody fusion. *Spine* 1993;18:1213–21.
- [6] Brantigan JW. Pseudarthrosis rate after allograft posterior lumbar interbody fusion with pedicle screw and plate fixation. *Spine* 1994;19:1271–9; discussion 1280.
- [7] Brantigan JW, Steffee AD. A carbon fiber implant to aid interbody lumbar fusion: two-year clinical results in the first 26 patients. *Spine* 1993;18:2106–7.
- [8] Brantigan JW, Steffee AD, Lewis ML, Quinn LM, Persenaire JM. Lumbar interbody fusion using the Brantigan I/F cage for posterior lumbar interbody fusion and the variable pedicle screw placement system: two-year results from a Food and Drug Administration investigational device exemption clinical trial. *Spine* 2000;25:1437–46.
- [9] Brantigan JW, Neidre A, Toohey JS. The Lumbar I/F Cage for posterior lumbar interbody fusion with the Variable Screw Placement System: 10-year results of a Food and Drug Administration clinical trial. *Spine J* 2004;4:681–8.
- [10] Stromberg L, Toohey JS, Neidre A, Ramsey M, Brantigan JW. Complications and surgical considerations in posterior lumbar interbody fusion with carbon fiber interbody cages and Steffee pedicle screws and plates. *Orthopedics* 2003;26:1039–43.
- [11] Prolo DJ, Oklund SA, Butcher M. Toward uniformity in evaluating results of lumbar spine operations: a paradigm applied to posterior lumbar interbody fusions. *Spine* 1986;11:601–6.
- [12] Bernhardt M, Bridwell KH. Segmental analysis of the sagittal plane alignment of the normal thoracic and lumbar spines and thoracolumbar junction. *Spine* 1989;14:717–21.
- [13] Yang SH, Chen PQ. Proximal kyphosis after short posterior fusion for thoracolumbar scoliosis. *Clin Orthop* 2003;411:152–8.
- [14] Cobb J. Outline for the study of scoliosis. Instructional Course Lectures, American Academy of Orthopedic Surgeons, 1948; 261–75.
- [15] Molz FJ, Kirkpatrick JS, Reza Moeini SM, Partin JI, Bidez MW. Effects of kyphosis and lordosis on the remaining lumbar vertebral levels within a thoracolumbar fusion: an experimental study of the multisegmental human spine. *J South Orthop Assoc* 1999;8:261–8.
- [16] Sink EL, Newton PO, Mubarak SJ, Wenger DR. Maintenance of sagittal plane alignment after surgical correction of spinal deformity in patients with cerebral palsy. *Spine* 2003;28:1396–403.
- [17] Vaccaro AR, Silber JS. Post-traumatic spinal deformity. *Spine* 2001;26(24 Suppl):S111–8.