



# Repair of Pars Interarticularis Defect With a Modified Cable-Screw Construct

Gordon R. Bozarth, MD, Guy R. Fogel, MD, John S. Toohey, MD, and Arvo Neidre, MD

*Operative treatment of symptomatic spondylolysis is not common. Multiple surgical techniques have been described for direct repairs of the pars defects. Reported success rates are high, although few reports describe successful return to sports in athletes. The purpose of the study was to assess the outcome after bone grafting and fixation of pars interarticularis defects utilizing a modification of the previously described techniques of Scott and of Songer.*

*A retrospective single-arm cohort study was performed at a single center. This article reports on three athletes with symptomatic spondylolysis or grade I spondylolisthesis unresponsive to conservative management who were treated with bone grafting and a screw-cable repair. The outcome measure was the return to sports activities. A retrospective chart and radiographic analysis was conducted on three athletes. Patients were assessed for return to sports, clinical evidence of return to functional activities, and radiographic evidence of healing of the pars defects. All three patients proceeded to radiographic and clinical success. All patients reported resolution of their preoperative pain and return to sports. One patient did require occasional anti-inflammatory drugs for episodic low back pain. The use of this modified cable-screw technique for symptomatic spondylolysis provided excellent clinical, radiographic, and functional results in this small cohort. (Journal of Surgical Orthopaedic Advances 16(2):0–0, 2007)*

Key words: pars defect, spondylolisthesis, spondylolysis

Spondylolysis and grade 1 spondylolisthesis are common defects found in the general population, with a reported incidence of 6% (1). While many remain asymptomatic or heal with bracing or symptomatic management, a small subgroup of these patients will continue to have significant functional limitations related to their sport (2). Symptomatic spondylolysis unresponsive to conservative management may be an indication for operative intervention. While lumbosacral fusion has remained the gold standard, direct repair of the pars defect has been shown to be effective in this subset (1, 3–9). Multiple surgical techniques have been described in an attempt to directly repair

the pars defect. Direct repair has the advantage of maintenance of the motion segment and compression across the bone-grafted pars defect. We have modified the Scott technique to pass a cable around a pedicle screw on each side, rather than the transverse process, and modified the Songer technique to pass the cable around the base of the spinous process and not beneath the lamina. We report on this modification for direct repair of symptomatic spondylolysis.

## Surgical Technique

The patient was positioned on a flexion frame in the prone position. Posterior laminar dissection was performed over the involved segment and a localization radiograph was obtained. Care was taken not to violate the facet capsule. The defect in the pars was localized bilaterally. Soft tissue and callus was debrided from each defect until bleeding bone was evident. Each pars defect was then bone grafted with iliac crest autograft. Pedicle screws were inserted within the pedicle at the same level

---

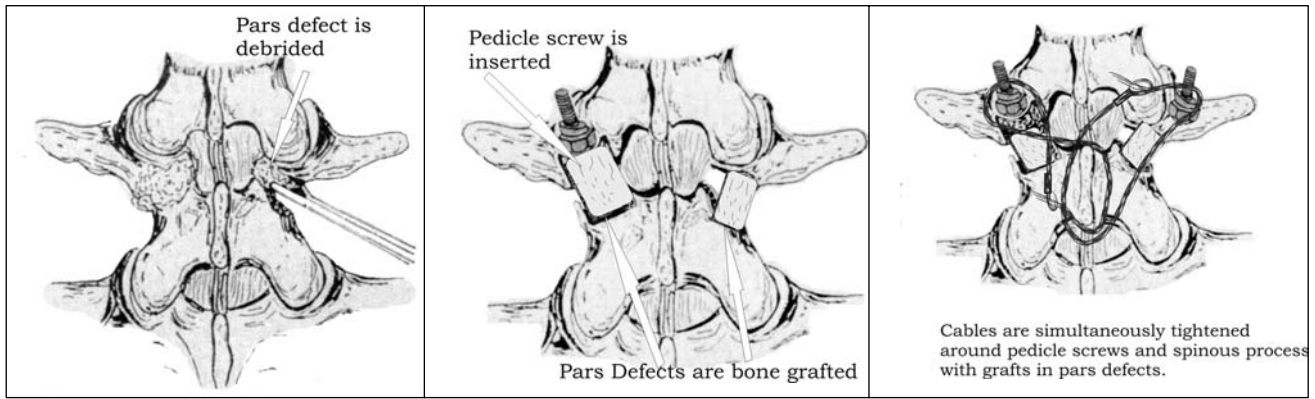
From South Texas Orthopaedic and Spinal Surgery Associates, San Antonio, TX. Address correspondence to: Guy R. Fogel, South Texas Orthopaedic and Spinal Surgery Associates, 9150 Huebner Road, San Antonio TX 78240; e-mail: [gfogel@spinetex.com](mailto:gfogel@spinetex.com).

No financial assistance was provided from any source for this study. Received for publication October 21, 2006; accepted for publication November 22, 2006.

For information on prices and availability of reprints call 410-494-4994 X226.

1548-825X/07/1602-0000\$22.00/0

Copyright © 2007 by the Southern Orthopaedic Association



**FIGURE 1** Surgical technique of modified Songer repair.

as the laminar pars defect, utilizing a standard technique. A 1-mm AcroMed Songer cable was then passed around the base of the spinous process and the ipsilateral pedicle screw from both sides at the involved level. The cables were then simultaneously tensioning and finally crimped. Figure 1 is a graphic representation of the procedure.

The surgical technique begins with debridement of the pars defect, then bone grafting of the pars defects with iliac crest autograft. Fixation is established with pedicle screw placement into each L5 pedicle, then a 1-mm cable is woven around the spinous process and both pedicle screws are tensioned to compress the pars defect bone grafts.

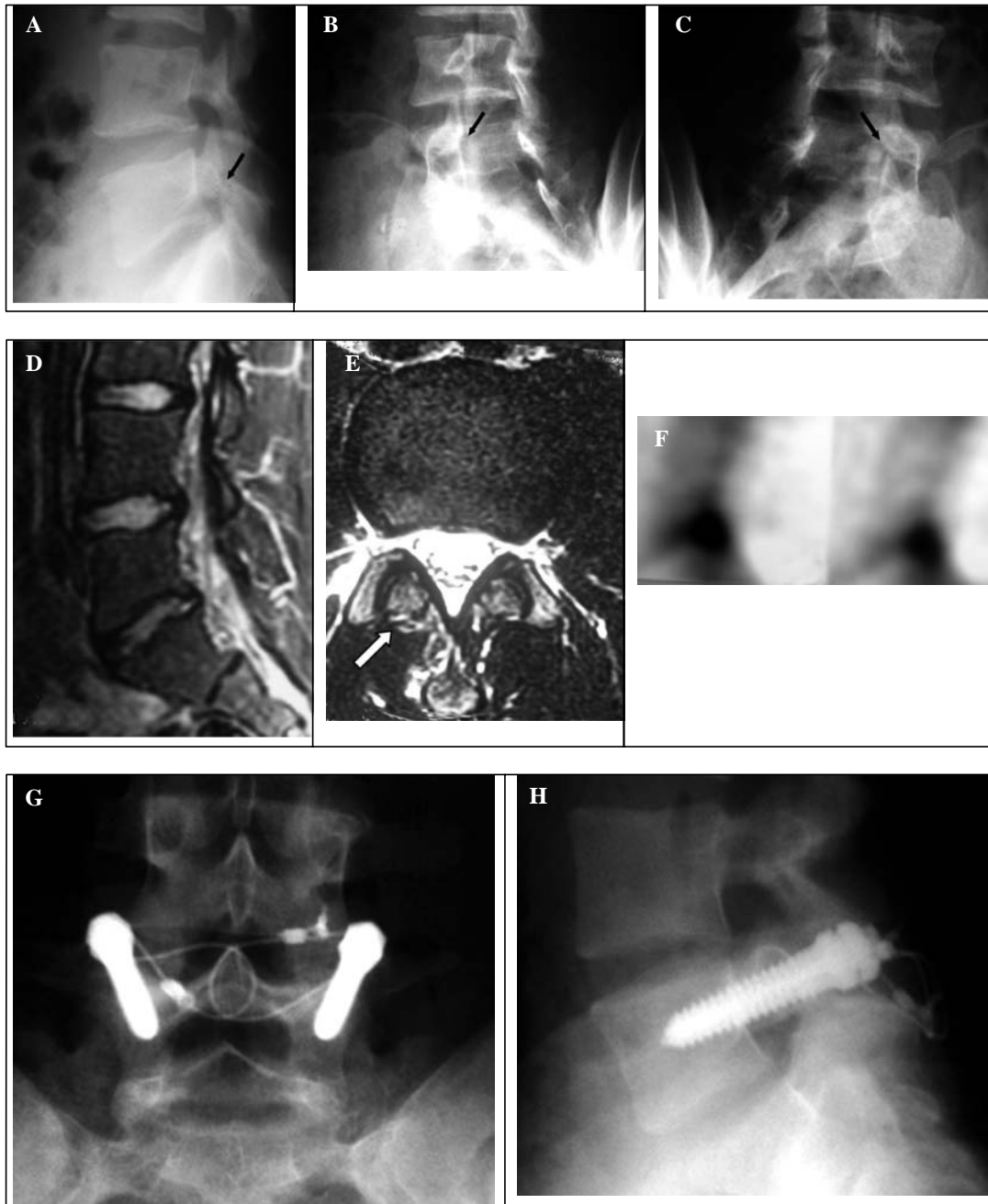### Case Reports

Patient 1 was a male 17-year-old soccer player with a 2-year history of back pain. His initial injury occurred while playing soccer. He complained of episodic significant low back pain that would limit his school attendance and he could not play soccer. Running became more painful, and basically any quick motion could be painful. He was treated with bracing, and had several rounds of physical therapy consisting of stretching and truncanal strengthening. Physical exam revealed negative straight leg raising and normal neurologic examination of the lower extremities. Plain x-rays, including obliques, showed pars defect of L5 bilaterally. A lumbar MRI scan revealed prominent pars defects with edema of the adjacent bone. A <sup>99m</sup>Tc bone scan showed increased uptake at the L5 level. The L5–S1 disc showed moderate dehydration. A discogram was done and was negative at L4–5 and L5–S1. Surgical repair of bilateral L5 pars defects was done. The patient was braced with a lumbar corset for 6 weeks. He returned to jogging at 6 weeks and returned to soccer at 3 months. At 6 months, he continued to play soccer; however, he complained of intermittent

stiffness of the low back. CT scan at 6 months after surgery showed one pars to be healed and one incompletely healed. At 1 year, the patient was asymptomatic and performing his usual soccer and conditioning program without limitations. CT scan at 1 year showed healing of both pars defects.

Patient 2 was a male 16-year-old baseball player with bilateral L5 pars defects. He was first diagnosed at age 14. He was treated with a brace and when pain free began gradual return to activities with physical therapy. He improved with conservative treatment and returned to full activity. He played school football, baseball, and other sports. He did return to playing high school baseball for the entire season. And then several weeks before his return visit, he began to have shooting pain to his left buttock following a diving fall to the ground. Physical exam showed mildly restrictive spine motion. Straight leg raising was negative. Leg lengths were equal. Plain x-rays of the lumbar spine showed a right-sided pars defect and the left pars appeared intact. CT scan showed bilateral L5 pars defects. A lumbar MRI scan showed Schmorl's nodes of several lumbar segments. Bone scan showed uptake of the left L5 pars defect and not the right. He had bilateral repair of the L5 pars defect. At 6 weeks, he was able to swim and jog. At 12 weeks, x-rays showed definite but incomplete healing of the pars defect bilaterally. He increased the amount and type of his aerobic activity. At 5 months, he was playing basketball and doing some running. Radiographs showed one side completely healed and the other side filling in. He began a full-time running program. At 8 months, he was jogging 1 mile. He continues to have some aching in his back. X-ray showed one pars defect completely healed and the opposite shows progressive healing. At 10 months, he was back to full basketball sports and running without discomfort. Radiograph showed apparent full healing of both of the pars defects.

AQ1

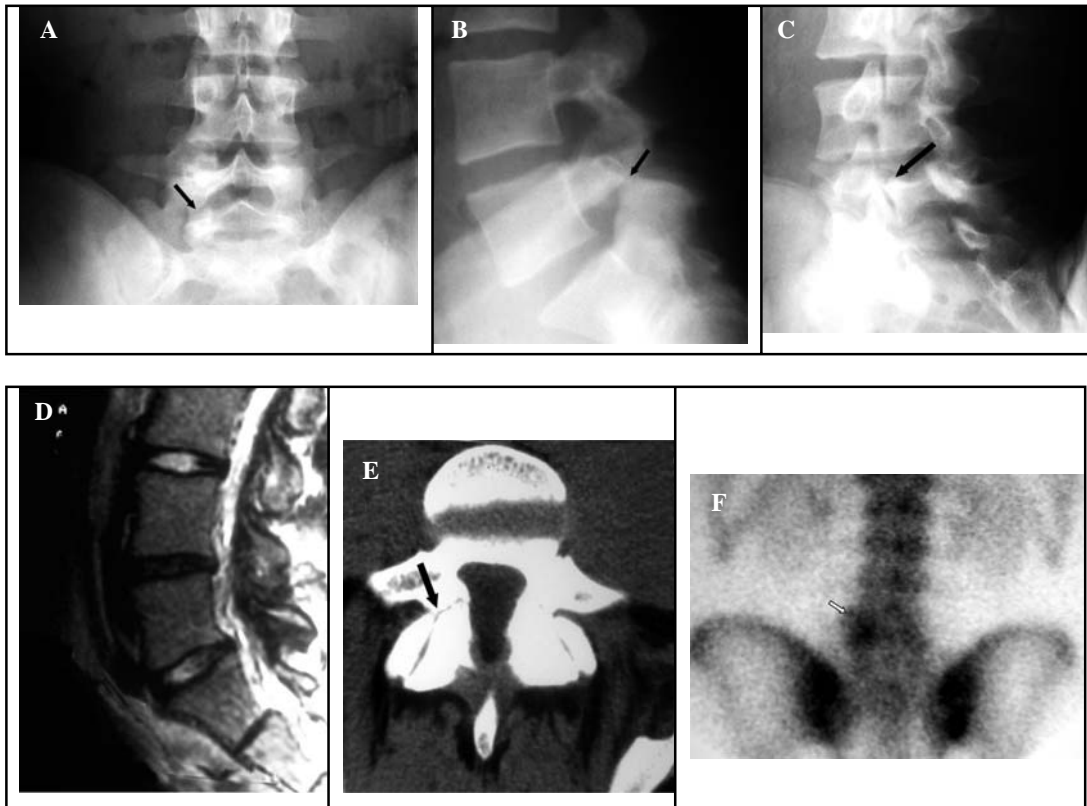


**FIGURE 2** A–C, lateral and oblique radiographs of L5 pars fractures with minimal slip. **A**, Lateral view suggests an L5 pars defect. **B** and **C**, Obliques confirm the pars defects bilaterally at L5. **D–F**, MRI and technetium-99 bone scan imaging of L5 pars defect. **D**, Sagittal MRI shows desiccation of the L5–S1 disc. **E**, Arrow demonstrates the pars defect. **F**, Lateral SPECT technetium-99 bone scan reveals increased uptake at the L5 level. **G** and **H**, AP and lateral x-rays of pars repair surgical technique. L5 pedicle screw fixation bilaterally with a Songer cable wound around the spinous process and tightened securely compressing graft in the pars defects.

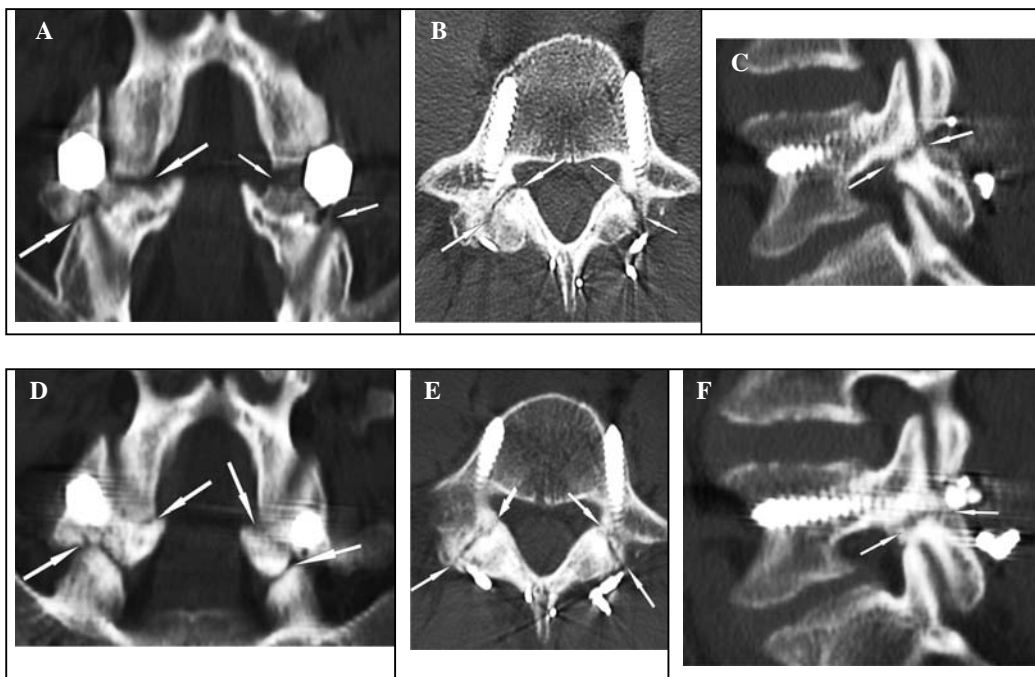
### Discussion

Several surgical techniques have been developed for surgical repair of symptomatic spondylolysis and up to grade 1 spondylolisthesis refractory to conservative management. Multiple wire, screw, screw-wire, pedicle screw-wire, pedicle screw-hook, and pedicle screw-rod

constructs have been described with a high rate of good to excellent results (3–5, 7, 9–13). These techniques are technically difficult and some require wire, hook, or cable passage beneath the posterior lamina or the transverse process (2, 4, 12, 14). The Scott technique describes a wiring beneath the transverse process on each side around the spinous process. Songer reported a special fabricated



**FIGURE 3** A–C, Preoperative AP, lateral, and oblique radiographs. **A**, AP view reveals abnormality reflecting a pars defect of the left L5 pars. **B**, Lateral view suggests a bilateral pars defect at L5. **C**, Arrow on the oblique x-ray demonstrates a pars defect. **D–F**, MRI and technetium-99 bone scan imaging of the L5 pars defect. **D**, MRI sagittal disc desiccation of L5–S1 without spondylolisthesis. **E**, CT axial view demonstrates a unilateral pars defect. **F**, Technetium-99 bone scan shows increased uptake of the unilateral pars defect.



**FIGURE 4** A–C, Six months postoperative CT scan. Coronal (**A**), axial (**B**), and sagittal (**C**) views demonstrating persistent incomplete healing of the pars defects repair. **D–F**, CT Scan at 1 year following surgical repair. Much improved healing of the pars defect bilaterally is evident.

pedicle screw with a hole in its head to allow passage of a 1-mm cable. This cable was passed from the pedicle screws around the spinous process and beneath the lamina. In our practice, there has been occasional loss of fixation with broken Scott wires. There is some hypothetical increased risk of nerve injury during blind passage of wires beneath the transverse process. Sublaminar passage of a cable may not be necessary. Our modification of previous techniques arose from a need for a stronger material with less breakage, and lower potential for neurologic complications related to wire passage beneath the transverse process or lamina.

The described modification to the Songer cable-pedicle screw technique does not involve the transverse process and does not require sublaminar cable passage, decreasing the degree of technical difficulty. Although the number of cases is small, all patients reported relief of their symptoms and were able to resume normal athletic activity. This suggests that a well-motivated athlete may return to his sport after a direct repair of pars defects for symptomatic spondylolysis.

## References

1. Fredrickson, B. E., Baker, D. McHolick, W. J. Yuan, H. A., Lubicky, J. P. The natural history of spondylolysis and spondylolisthesis. *J. Bone Joint Surg.* 66-A(5):699–707, 1984.
2. Songer, M. N., Rovin, R. Repair of the pars interarticularis defect with a cable-screw construct. A preliminary report. *Spine* 23(2):263–269, 1998.
3. Gillet, P., Petit, M. Direct repair of spondylolysis without spondylolisthesis, using a rod-screw construct and bone grafting of the pars defect. *Spine* 24(12):1252–1256, 1999.
4. Askar, Z., Wardlaw, D., Koti, M. Scott wiring for direct repair of lumbar spondylolysis. *Spine* 28(4):354–357, 2003.
5. Tokuhashi, Y., Matsuzaki, H. Repair of defects in spondylolysis by segmental pedicular screw hook fixation. A preliminary report. *Spine* 21(17):2041–2045, 1996.
6. Reitman, C. A., Esses, S. I. Direct repair of spondylolytic defects in young competitive athletes. *Spine J.* 2(2):142–144, 2002.
7. Wu, S. S., Lee, C. H., Chen, P. Q. Operative repair of symptomatic spondylolysis following a positive response to diagnostic pars injection. *J. Spinal Disord.* 12(1):10–16, 1999.
8. Roca, J., Moretta, D., Fuster, S., Roca, A. Direct repair of spondylolysis. *Clin. Orthop.* 246:86–91, 1989.
9. Buck, J. E. Direct repair of the defect in spondylolisthesis. Preliminary report. *J. Bone Joint Surg.* 52-B(3):432–437, 1970.
10. Pedersen, A. K., Hagen, R. Spondylolysis and spondylolisthesis. Treatment by internal fixation and bone-grafting of the defect. *J. Bone Joint Surg.* 70-A(1):15–24, 1988.
11. Ivanic, G. M., Pink, T. P., Achatz, W., Ward, J. C., Homann, N. C., May, M. Direct stabilization of lumbar spondylolysis with a hook screw: mean 11-year follow-up period for 113 patients. *Spine* 28(3):255–259, 2003.
12. Johnson, G. V., Thompson, A. G. The Scott wiring technique for direct repair of lumbar spondylolysis. *J. Bone Joint Surg.* 74-B(3):426–430, 1992.
13. Kakiuchi, M. Repair of the defect in spondylolysis. Durable fixation with pedicle screws and laminar hooks. *J. Bone Joint Surg.* 79-A(6):818–825, 1997.
14. Hefti, F., Seelig, W., Morscher, E. Repair of lumbar spondylolysis with a hook-screw. *Int. Orthop.* 16(1):81–85, 1992.

---

**QUERIES TO BE ANSWERED BY AUTHOR**

**IMPORTANT NOTE: Please mark your corrections and answers to these queries directly onto the proof at the relevant place. Do NOT mark your corrections on this query sheet.**

---

**Queries from the Copyeditor:**

AQ1 Pls verify spelling change

---